

**PATIENT**

Kiowa George Gordes

SPECIES

Canine

BREED

Greyhound

SEX

MN

AGE

2012

WEIGHT

88.7lbs

INTERPRETED BYMaggie Machen
Lamy, DVM, DACVIM
(Cardiology)**HOSPITAL NAME**

Fullerton

REFERRING VET

Dr. Unger

PRESENTING CLINICAL SIGNS

History: Presented for exam and vaccines. Grade 1-2/6 heart murmur with VPC's noted. History of a grain free diet.

-ECG report (Idexx): Sinus with intermittent single VPCs. The QRS complexes are wide and tall suggestive of left ventricular enlargement. The patient waves are tall suggestive of left atrial enlargement. All other ECG parameters are within normal limits and no therapy was recommended.

-Sedation used: Sedation not required.

-STAT: Not requested.

ECHOCARDIOGRAM FINDINGS

2D, m-mode, color flow and doppler imaging is available. Mitral valve is mildly thickened with no prolapse into the left atrial lumen. No mitral regurgitation with normal left atrial dimension. Normal LV diameter with adequate myocardial function. The tricuspid valve appears normal with no tricuspid regurgitation. Normal right atrial and ventricular diameter and morphology indicating no overt evidence of pulmonary arterial hypertension. The pulmonic and aortic valves are normal in morphology and mobility. Normal pulmonic and aortic outflow velocities with laminar flow. No obvious aortic and pulmonic insufficiency. No pericardial or pleural effusion noted. No obvious cardiac masses.

CARDIAC CHART

CANINE CARDIAC PARAMETERS	MR VMAX (m/s)	TR VMAX (m/s)	LA/AO (Boon method)	LA/AO (Heart Base; Swe)	FS (%)	EF (%)	EPSS (cm)
NORMAL PARAMETER	4.5-5.5	<2.7	1.3	<1.6	28-40	40-100	<0.6
PATIENT	NA	NA	NM	1.0	41	71	NM
CANINE CARDIAC PARAMETERS	HR (BPM)	AV VMAX (m/s)	PV MAX (m/s)	BODY WEIGHT (kg)	LA 2D short axis Base view (cm)	LVIDd Avg; 2D and m-mode short axis (cm)	LVIDs Avg; 2D and m-mode short axis (cm)
NORMAL PARAMETER	50-100	0.7-1.7	0.7-1.6	BELOW	BELOW	BELOW	BELOW
PATIENT	126	1.4	1.2	40.2	2.6	4.9	3.0
*Normal chamber parameters expressed as a mean value (SD)				3	1.27 (5.3)	2.46 (2.46)	1.36 (5.5)
BODY WEIGHT DEPENDENT PARAMETERS				5	1.40 (4.5)	2.74 (5.2)	1.60 (4.7)
*Note: All measurements based upon multi-modal images and methods. An average value is reported.				10	1.50 (3.8)	3.27 (3.5)	2.06 (3.1)
				15	1.83 (2.0)	3.71 (2.4)	2.43 (2.1)
				20	2.02 (1.9)	4.14 (2.2)	2.80 (2.0)
Adapted from June Boon, Veterinary Echocardiography, 1998				25	2.18 (2.4)	4.48 (2.9)	3.10 (2.5)
Rishniw M and Hollis NE, J Vet Intern Med 2000; 14:429-435				30	2.33 (3.3)	4.83 (3.9)	3.39 (3.4)
Hansson et al, Vet Rad and Ultrasound 2002				35	2.48 (4.3)	5.17 (5.0)	3.69 (4.5)
Bonagura et al. Echocardiography: principles of interpretation, Vet Clin North Am 15:1177, 1995				40	2.62 (5.2)	5.48 (6.1)	3.96 (5.4)
				50	2.88 (7.1)	6.07 (8.3)	4.46 (7.4)

INVOICE

21364

DATE

10/5/21

INTERPRETATION OF THE FINDINGS & FURTHER RECOMMENDATIONS

Overtly normal cardiac dimensions and function, with no obvious dysfunction or dilation of the left heart. No evidence of pulmonary hypertension or significant valve leaks. No obvious cause for the murmur identified, making it likely physiologic in origin (common in this breed). No evidence of diet-related cardiomyopathy; however, the conservative recommendation for a diet change is ideal.

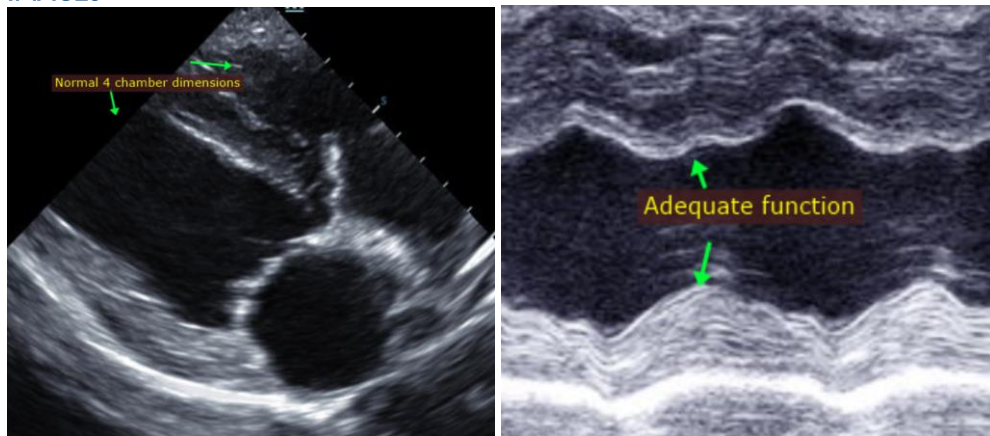
No structural cause for VPCs is identified. Consider systemic or primary arrhythmic causes in this young puppy. Treatment and/or further evaluation should be dictated by the ECG report.

No structural contraindication for general anesthesia; however, this does not address the arrhythmia. Anesthetic guidelines should be dictated by the amount and complexity of the arrhythmia.

Monitor for development of a heart murmur, cough, labored breathing, exercise intolerance or collapse episodes.

A recheck echocardiogram is recommended in 1 year to screen for development of disease the preexisting murmur may mask.

IMAGES



The information and recommendations provided are based on the images presented by the referring veterinarian. No evaluation can be communicated regarding pathology that was not visible in the image/video clips provided.

Thank you for this referral. This report was generated using transcription software, and minor dictation errors may be present. If the clinical or image interpretation does not parallel your findings or if I can be of any further assistance, please contact me.

Maggie Machen Lamy, DVM
Diplomate of the American College of Veterinary Internal Medicine (Cardiology)
info@sonopath.com